






Superficial bursitis

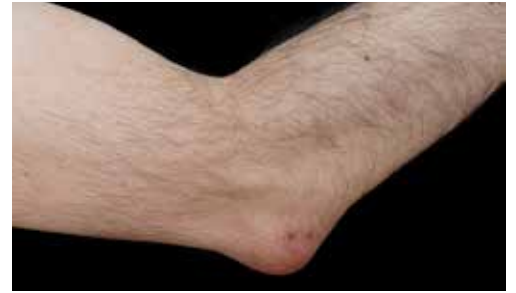Bursitis refers to enlargement of a bursa, but the term is something of a misnomer as in many cases there is no true inflammation present. Superficial bursitis usually results from chronic microtrauma but can also be related to systemic inflammatory conditions or infection. Bursitis (along with tendonitis) is one of the top 25 most common problems managed in Australian general practice. Other types of bursitis e.g. subacromial, GTPS, are not dealt with in this teaching plan.

<p>TEACHING AND LEARNING AREAS</p> 	<ul style="list-style-type: none"> • Aetiology of superficial bursitis - acute traumatic (haemorrhagic), chronic aseptic (due to microtraumatic, or inflammatory causes), or septic • Common superficial bursitides - olecranon, prepatellar, infrapatellar, and calcaneal • Clinical features of various presentations of superficial bursitis • Red flag risk factors, symptoms and signs for septic bursitis • How to perform superficial bursal aspiration • Indications for investigations • Approach to treatment for specific types of superficial bursitis • Indications for surgical referral and appropriate pathways 				
<p>PRE-SESSION ACTIVITIES</p> 	<ul style="list-style-type: none"> • Read the 2017 AAFP article Common Superficial Bursitis 				
<p>TEACHING TIPS AND TRAPS</p> 	<ul style="list-style-type: none"> • The diagnosis of superficial bursitis is usually clinical and imaging is only required for specific indications • Acute traumatic and chronic microtrauma bursitis should be managed conservatively • Intrabursal corticosteroid injection should not be routinely used in the management of aseptic microtraumatic superficial bursitis • Inflammatory bursitis is usually related to crystal diseases or inflammatory arthritic disorders e.g. rheumatoid arthritis • S. aureus is responsible for the most septic superficial bursitis • If infection is suspected, bursal aspiration should be performed 				
<p>RESOURCES</p> 	<table border="1"> <tbody> <tr> <td data-bbox="325 1747 430 1854">Read</td> <td data-bbox="430 1747 1498 1854"> <ul style="list-style-type: none"> • Therapeutic Guidelines chapter on Septic Bursitis • Pub Med StatPearls Bursitis </td> </tr> <tr> <td data-bbox="325 1854 430 1937">Watch</td> <td data-bbox="430 1854 1498 1937"> <ul style="list-style-type: none"> • Olecranon bursa aspiration </td> </tr> </tbody> </table>	Read	<ul style="list-style-type: none"> • Therapeutic Guidelines chapter on Septic Bursitis • Pub Med StatPearls Bursitis 	Watch	<ul style="list-style-type: none"> • Olecranon bursa aspiration
Read	<ul style="list-style-type: none"> • Therapeutic Guidelines chapter on Septic Bursitis • Pub Med StatPearls Bursitis 				
Watch	<ul style="list-style-type: none"> • Olecranon bursa aspiration 				
<p>FOLLOW UP & EXTENSION ACTIVITIES</p> 	<ul style="list-style-type: none"> • Registrar to undertake clinical reasoning challenge and discuss with supervisor 				

Superficial bursitis

Clinical Reasoning Challenge

Donald, aged 64, is a retired architect and presents to you with a swelling over his right elbow for the past 6 weeks. It has slowly become bigger over this time.



QUESTION 1. What are the KEY FEATURES on history to help exclude a more serious cause for this problem?

List up to FOUR key features.

1. _____

2. _____

3. _____

4. _____

QUESTION 2. Further history taking is unremarkable. What is the single MOST LIKELY diagnosis for Donald's presentation?

List ONE diagnosis.

QUESTION 3. What are the MOST APPROPRIATE initial management steps at this stage?

List up to THREE initial management steps.

1. _____

2. _____

3. _____

Superficial bursitis

ANSWERS

QUESTION 1

What are the KEY FEATURES on history to help exclude a more serious cause for this problem?

- Pain
- Fever
- Reduced ROM joint
- Trauma
- History of inflammatory arthritis e.g. gout, rheumatoid arthritis

QUESTION 2

Further history taking is unremarkable. What is the single MOST LIKELY diagnosis for Donald's presentation?

- Chronic non-inflammatory olecranon bursitis

QUESTION 3

What are the MOST APPROPRIATE initial management steps at this stage?

- Avoid leaning on elbow/exacerbating activities
- Compression bandaging
- Advise likely to resolve spontaneously